

# Late outcome of anterior versus posterior fixation for Thoraco-lumbar fractures

Ahmed Elsawaf

Department of Neurosurgery, Suez Canal University Hospital, Ismailia, Egypt

## Abstract

There is no clear study comparing the long-term outcome of either anterior or posterior fixation approaches for thoracolumbar fractures. To get a comparative analysis of the overall late outcome of both approaches, a total of 60 patients with unstable thoracolumbar fracture were classified into two groups; Group I (n=30) included those who were operated by posterior decompression and pedicle screw fixation, Group II (n=30) included patients who were operated by anterior neuro-decompression and fixation. After a mean of 4.9 years, patients were followed clinically according to Frankel Motor grading scale and Prolo economic / function outcome scale. Urodynamic studies and Sexual Health Inventory for Men (SHIM) scale were also undertaken. Patients underwent radiological evaluation of the sagittal alignment by measuring the kyphotic angle (KA) and regional kyphosis angle (RA). At final follow-up, significant neurological improvement was demonstrated in the anterior approach group. Functional outcome also showed statistically significant improvement ( $P<0.005$ ) in anterior group with a 76.7% of patients showed excellent outcome; whereas excellent functional outcome was achieved in 50% only of posterior group. Both techniques resulted in statistically significant initial improvement in sagittal alignment (KA and RA), however, the posterior group lost this significance at follow-up whereas the anterior- group continued to demonstrate statistically significant improvement in sagittal alignment at follow-up  $P= 0.007$ . Restoring the anterior column stability to prevent future increased kyphotic deformity after obtaining initial correction has a long term significant correlation with the overall clinical and functional improvement.

**Keywords:** Thoraco-lumbar fractures – Anterior fixation – Posterior fixation.

## INTRODUCTION

Burst fractures account for 21–58% of all thoraco-lumbar fractures (Dai et al., 2004; Denis, 1983; Gertzbein, 1992; McLain, 2006). These fractures often result in a significant instability of the spine and lead to acute or delayed neurological deficits. Most authors agree that unstable burst thoracolumbar fractures require surgical treatment, but which specific approach should be used for the treatment is still controversial (Chen et al., 2012; Wood et al., 2005). Many surgeons prefer to utilize posterior decompression and transpedicular instrumentation believing that spinal realignment and the indirect reduction of bone fragments by ligamentotaxis and direct posterior or transpedicular decompression could provide satisfactory neural decompression (Alvine et al., 2004; Fredrickson et al., 1992; Willén et al., 1990). The use of pedicle screw plates for spinal fixation was introduced in 1963 by Roy-Camille and associates (Roy-

Camille et al., 1970) and it is still the most familiar to spine surgeons till now.

On the other hand, other surgeons advocate an anterior-only approach to directly decompress the neural elements followed by internal fixation (Carl et al., 2000; Esses et al., 1990; Kaneda et al., 1984). Anterior approaches had begun in 1928 when Royle (1928) started to use anterior decompression for the treatment of scoliosis, but the first anterior instrumentation was described by Humpharies and Hawk (1958) in 1958 for the treatment of Pott's diseases. After this, many construct designs were introduced with some problems in strength and biomechanics. Now, the new titanium made constructs such as the Kaneda and Z-Plate II have many biomechanical advantages than those of previous constructs.

Most studies comparing either approach are retrospe-

**Table 1.** Frankel Grading Scale

<b>A:</b> Complete, No motor or sensory function
<b>B:</b> Sensory only, No motor function, preservation of sensory function
<b>C:</b> Motor useless Some motor function present, but not useful
<b>D:</b> Motor useful, Motor function present but somewhat weak
<b>E:</b> Intact, Normal sensory and motor function

retrospective with a short term follow-up periods (Dai et al., 2007; Korovessis et al., 2006). There is no clear study comparing the long-term efficacy of either approaches regarding the overall clinical improvement, return to normal life, late-onset complications and also late radiological assessment. The aim of this study is to compare the long term outcome after either posterior or anterior approaches, trying to understand the natural behavior of both techniques, the impact of complete or incomplete decompression in either anterior or posterior approaches respectively on the overall neurological recovery and the clinical and functional fate of those patients underwent these two types of surgery.

## CLINICAL MATERIALS AND METHODS

### Patient population

This is a prospective Double-blinded, randomized, controlled, crossover long-term study on patients with a single-level unstable burst thoracolumbar fracture between D11 and L2. In the period between March 2004 and February 2006, a consecutive series of sixty patients (44 male and 16 females) were subjected to surgical neuro-decompression and spinal fixation who were found to be included in the following surgical indications for surgical intervention: 1) neurological deficit symptoms including motor weakness, 2) vertebral body compression more than 40%, 3) bony fragment encroachment upon the spinal canal of more than 50%, 4) kyphotic deformity of more than 30 degrees, and 5) injury to all three vertebral columns. Patients having one of these findings were treated operatively (Benson et al., 1992; Willén et al., 1990).

The most frequent fractured level was L-1 (45%) then L-2 (24%), D-12 (22%) while the lowest frequency of the fractured level was D-11 (9%).

The patients were randomly divided into two groups according to the procedure that would be done: Group I: 30 patients treated by posterior decompression and fixation by transpedicular screws, plates and rods. Usually long segment fixation; two levels above and one level below, or two levels above and two levels below

Group II: 30 patients treated by anterior decompression and fixation utilizing a corpectomy strut graft and a thoraco-lumbar plating system.

### Clinical assessment

On admission, neurological status was assessed using the Frankel motor score system (11). For group I; 6 patients were neurologically intact "Frankel E" (Table.1), and 24 patients were sustained neurological injury, those are classified as follow: 11 patients on Frankel "D" (5 Patients of those have had conus medullaris syndrome and 4 patients have had cauda equina syndrome), while 6 patients on Frankel "C" (all of them have had conus medullaris syndrome), and 4 patient had incomplete paraplegia "Frankel B", 3 patients were paraplegic at the time of the accident and was categorized as Frankel "A".

Whereas for group II, 9 patients were neurologically intact "Frankel E", and 21 patients were sustained neurological injury, those are classified as follow: 9 patients on Frankel "D" (4 Patients of those have had conus medullaris syndrome and 2 patients have had cauda equina syndrome), while 8 patients on Frankel "C" (all have had conus medullaris syndrome), and 3 patients on Frankel "B", and 1 patient was considered complete paraplegic Frankel "A".

### Functional outcome

Return to work properly and residual pain after passing a time of fixation surgery may be considered the most important aspect of evaluating efficacy of a technique. In our study, we try to get an idea about the pattern of life after thoraco-lumbar fixation either going to normal or completely different from preoperative one. The functional (pain) outcome in this series is based on modified Prolo Functional and Economic Rating Scale (Table 2) ( Prolo et al., 1986).

### Sexual function

The extent of erectile dysfunction is delineated in our

**Table 2.** Modified Prolo Functional and Economic Rating Scale

<b>Economic (activity) grade</b>
1- Complete invalid (worse)
2- No gainful occupation (including housework or retirement activities)
3- Working /active but not at premorbid level
4- Working /active at previous level with limitation
5- Working /active at previous level without limitation
<b>Functional (pain) grade</b>
1- Total incapacity (worse).
2- Moderate to severe daily pain (no change)
3- Low level of daily pain (improved)
4- Occasional or episodic pain
5- No pain

**Table 3.** Sexual Health Inventory for Men (SHIM)

<p>1. How do you rate your confidence that you could get and keep an erection?</p> <p>2. When you had erections with sexual stimulation, how often were your erections hard enough for penetration?</p> <p>3. During sexual intercourse, how often were you able to maintain your erection after you had penetrated (entered) your partner?</p> <p>4. During sexual intercourse, how difficult was it to maintain your erection to completion of intercourse?</p> <p>5. When you attempted sexual intercourse, how often was it satisfactory for you</p>
<p>The score characterizes ED severity. Total score ranges from 5 to 25 and is based on five questions. Each rated on a Likert scale of 1 □□least functional to 5□□□most functional.</p> <p>22–25 Normal erectile function</p> <p>17–21 Mild ED</p> <p>12–16 Mild to moderate ED</p> <p>8–11 Moderate ED</p> <p>&lt;7 Severe ED</p>

study using the Sexual Health Inventory for Men (SHIM) (Cappelleri and Rosen, 2005), which has five questions, detailed in Table 3. The five questions are simple, straightforward, yet comprehensive.

### Demographic data

This is a prospective study with a mean follow-up period of 4.9 years (39 – 64 months). Patients were followed at 3, 4 and 5 years postoperatively they were clinically and

radiologically assessed at these periods of follow-up. Both of the two study groups were similar regarding to age, gender, weight, load-sharing scores, trauma-surgery interval, kyphosis angle, anterior compression rate, and canal encroachment.

### Radiological assessment

All the patients are subjected to full radiological examination including:

**Table 4.** Demographic data including Age, Sex, and trauma-surgery interval measured by hours, preoperative and postoperative radiological data (Cobb angle and percent of canal encroachment) for the posterior fixation group. (Group 1)

No.	age	sex	trauma-surgery interval	Preoperative kyphotic angle	Postoperative kyphotic angle	Preoperative canal encroachment	postoperative canal encroachment
1	22	M	7	20.3	9.1	55%	45%
2	17	M	13	24.4	9.6	35%	25%
3	31	M	21	22.7	11.2	45%	30%
4	24	M	11	18.3	8.8	55%	45%
5	28	F	10	26.1	7.5	50%	40%
6	41	M	9	22.2	11.4	40%	20%
7	28	F	22	23	9.1	60%	40%
8	21	M	31	20.6	10	50%	30%
9	17	M	16	19.9	10.3	50%	40%
10	32	F	14	24.5	11	45%	30%
11	19	M	6	23	9	55%	20%
12	21	F	19	22.3	11.9	55%	25%
13	26	M	24	22.8	6.9	50%	30%
14	46	F	21	21.2	8.8	60%	35%
15	17	M	11	19.9	9.9	50%	20%
16	17	M	7	25.4	13.2	50%	20%
17	19	M	15	24.8	8.7	55%	25%
18	21	M	19	23.9	8.4	80%	50%
19	16	M	16	21.9	11.3	45%	35%
20	26	M	23	20.3	10.3	50%	20%
21	25	M	25	18.7	8.6	60%	40%
22	31	F	21	19.2	9.3	70%	40%
23	32	M	13	21.6	8.5	50%	20%
24	25	F	9	19.4	12.5	55%	30%
25	27	M	21	20	9.2	50%	30%
26	20	M	21	20.6	11	35%	20%
27	21	M	24	22.7	12.2	50%	40%
28	18	M	21	26.7	11.1	60%	35%
29	33	M	12	25	8.2	65%	25%
30	19	M	26	23.6	9.9	55%	31%

A) X-ray studies including lateral, Antero-posterior, oblique views. Flexion-Extension views were done in selected patients with caution of marked instability. The following parameters are measured both pre- and post-operatively and statistically compared: Kyphotic angle (KA) is the angle between the superior and inferior vertebral endplate of the fractured vertebra, the regional kyphosis angle (RA) is as the angle between the superior endplate of the superior adjacent vertebra and the inferior endplate of the inferior adjacent vertebra.

B) Thin cuts computerized tomography (CT) scanning: including the fracture level and two levels above and two levels below. The percentage of canal encroachment was assessed in all patients. Transverse diameter of the spinal canal at the level of preoperative maximal canal encroachment was also assessed using thin cuts CT

scans.

C) MRI was done but not regular in all cases.

### Surgical procedure

The 30 patients of the posterior approach underwent partial or complete laminectomy followed by posterior or transpedicular decompression of the fragment, indirect spinal decompression by ligamentotaxis, and long-segment fixation achieved by pedicle screw fixators (Isola, Johnson and Johnson, USA) usually two levels above and one level below, or two levels above and two levels below. Distraction, compression, or restoration of lordosis was used to correct the spinal deformity. Posterior or postero-lateral fusion was then added.

**Table 5.** Demographic data including Age, Sex, and trauma-surgery interval measured by hours, preoperative and postoperative radiological data (Cobb angle and percent of canal encroachment) for the anterior fixation group. (Group II)

No.	age	sex	trauma-surgery interval (Hours)	Preoperative kyphotic angle	Postoperative kyphotic angle	Preoperative canal encroachment	Postoperative canal encroachment
1	18	M	12	14.5	4.2	60%	30%
2	22	M	4	18.3	5.2	75%	20%
3	23	F	6	17.2	9.1	60%	10%
4	43	M	18	11.9	5.2	66%	10%
5	21	M	9	20.1	9.2	50%	5%
6	32	F	15	18.3	6.1	45%	20%
7	21	M	5	21.2	5.6	30%	3%
8	26	M	7	13.9	5.5	45%	5%
9	25	M	22	20.8	6.2	30%	0%
10	31	M	13	22.3	4.4	30%	5%
11	20	F	21	18.4	7.4	45%	20%
12	18	M	6	19.5	5.1	65%	20%
13	23	M	9	20.7	6.1	40%	0%
14	29	M	11	13.8	8.2	40%	3%
15	28	F	20	22.4	10.3	80%	4%
16	21	F	16	23.5	7.3	20%	6%
17	23	M	23	20.5	8.4	50%	3%
18	42	M	31	18.5	5.5	40%	10%
19	35	M	15	17.8	7.7	45%	10%
20	24	M	17	21.6	8.9	45%	5%
21	30	M	21	20.3	6.7	40%	3%
22	17	F	8	20	6.4	50%	5%
23	26	M	4	18.7	6.8	40%	15%
24	36	F	22	23.5	6.4	30%	0%
25	24	M	19	15.9	6.7	30%	4%
26	19	M	21	22.8	4.3	60%	10%
27	21	F	17	24.8	9.6	45%	5%
28	28	F	24	20	8.8	50%	10%
29	34	M	6	21	8	40%	3%
30	27	M	11	20	6.1	46%	8%

In the anterior approach group, a left-sided 11th or 12th rib extrapleural-retroperitoneal approach was used to expose fractured vertebrae. A subtotal corpectomy was performed and the spinal canal was fully decompressed. The dura was visualized through the cranio-caudal retraction of the fractured vertebrae and mediolateral retraction from one pedicle to the other. After neuro-decompression, either bony fragments of the corpectomy or a harvested rib was set into the vertebral body defect. Screw with rods (Atlas, Medcraft, France) was used in the 30 patients of the anterior approach group.

## RESULTS

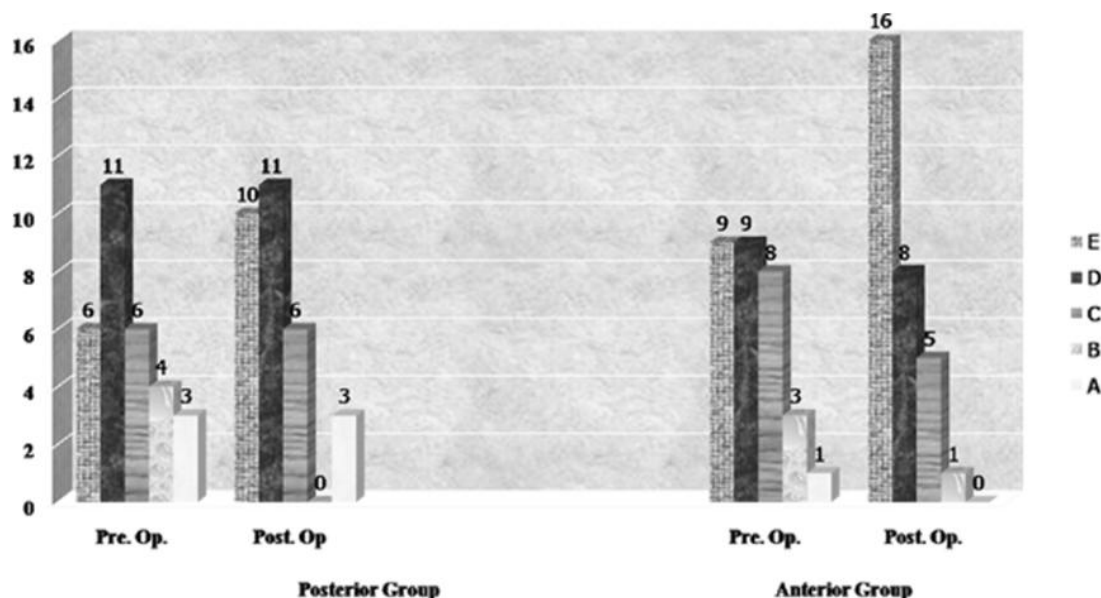
As expected, a correlation was found between clinical neurological recovery and the severity of initial spinal

cord and roots injuries in both groups; the patients who had severe preoperative clinical/radiological neurological injury had the worst prognosis, and the patients had a good preoperative neurological scores had a better outcome.

## Clinical outcome

The Frankle classification system was used:

Regarding the posterior group (group I): on admission; 6 patients were neurologically intact "Frankle grade E", and remained on the same grade at the follow-up time. Eleven patients sustained some weakness of motor power and graded as D, 4 of them had recovered full motor and sensory function "Frankle Grade E" at final follow-up examination (3 of them had preoperative cauda



**Figure 1.** Clinical outcome according to Frankle grading system

equine syndrome and 1 had conus injury), and 7 patients remained on the same grade. Of the 6 patients who were preoperatively presented as Frankle grade C, 2 of them improved one grade and four patients remained the same. The 4 patients who were presented as grade B on admission, 2 of them improved to grade C and two improved significantly but still have only some dyesthesia and numbness (grade D). Regarding the 3 patients with grade A, no significant improvement was shown at the final follow-up (Figure 1).

For the anterior group (group II): On admission, 9 patients were neurologically intact "Frankle Grade E", and these 9 patients remained at the follow-up without having additional surgery-related neurological injury. Nine patients were Frankle Grade "D", 7 of them had recovered full motor and sensory function "Grade E" at final follow-up examination, and two patients remained on grade "D". Eight patients were Frankle Grade "C", 6 of them had improved one grade and 2 patients remained at the same grade. Three patients were Frankle Grade "B" and all of them had improved one grade. The last patient with grade "A" showed some superficial sensation at both lower extremities grade "B" at the final follow-up (Figure 1).

Significant correlation regarding neurological improvement measured by Frankle Paraplegia Scale showed more significant improvement in anterior group rather than posterior group,  $P < 0.005$ .

Regarding long-term operative complications of both approaches. In group I; there were no patients deteriorated neurologically as a result of operative technique. One patient developed post-operative radicular pain and improved with medical treatment. There were no instances of pseudarthrosis or hardware

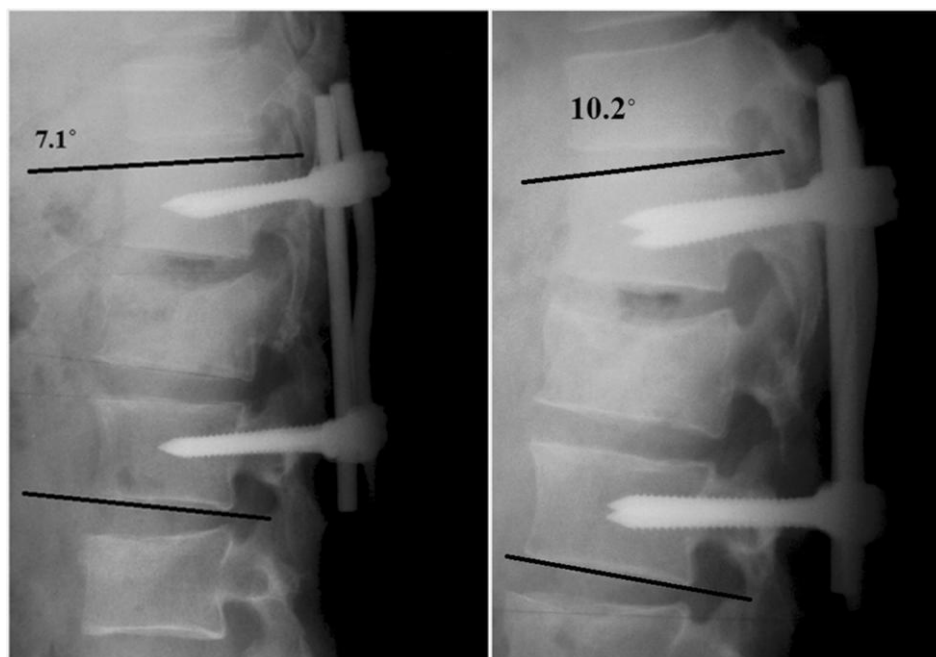
breakage. In group II: Also, there were no patients deteriorated neurologically as a result of operative treatment. One patient developed partial pullout of one of the superior screws without displacement of the implant or progression during the follow up period. A solid fusion had already been achieved in this patient, and no additional treatment was required. One patient was exposed to intra-operative sympathetic plexus injury on the operative side (left side) and developed unilateral lower limb vasogenic changes but improved during the follow up period.

### Functional outcome

Regarding posterior group (group I): Outcome based on *modified Prolo Functional Economic Rating Scale* in posterior group showed that 15 patients (50%) had excellent pain relief and working /active at previous level without limitation, 9 patients (30%) had good pain relief and working /active at previous level with limitation and 6 patients (20%) had fair pain results but no gainful occupation.

In comparison to posterior group, the anterior fixation group showed statistically significant improvement ( $P < 0.005$ ); 23 patients (76.7%) had excellent pain relief and working /active at previous level without limitation, 6 patients (20%) had good pain relief and working /active at previous level with limitation and 1 patient (3.3%) had fair pain result and working /active but not at pre-morbid level.

Regarding uro-dynamics condition, for group I, 18 patients had urinary symptoms in the form of urine retention. With continues follow-up, 11 patients showed progressive improvement and all of them were not using urinary catheter anymore, 4 patients had initial improve-



**Figure 2.** Loss of initial improvement in sagittal alignment in posterior fixation group, A: immediate postoperative, B: at final follow-up

ment but with long term follow-up they had detrusor muscle insufficiency, they had distension overflow; two of them had back pressure on the kidney and needed intermittent catheterization to relieve the pressure, the remaining two patients showed no improvement of urinary retention.

On the other hand group B showed 16 patients of acute urinary dysfunction, 13 of them had complete improvement of the problem by the follow-up period, the other 3 patients had persistent urinary dysfunction but was in need for only intermittent catheterization with bladder distension.

Sexual functions assessed according to the Sexual Health Inventory for Men (SHIM) (Cappelleri and Rosen, 2005): In the posterior group (including 20 males), one month after surgery, 6 patients were considered as normal, 6 patients were mild, 5 were mild to moderate, 1 were moderate and 2 were severe. At the final follow-up, it showed better results with medical treatment only: It was 7 normal, 10 mild, 1 mild to normal, 0 moderate, 2 severe. On the other hand, in anterior group (including 24 males) there were 8 patients intact sexually at one month after surgery, 5 had mild affection, 7 moderate to mild, 3 moderate, and 1 severe. At final follow-up, it was as follow: 12 were normal sexually, 5 had mild affection, 4 were mild to moderate, 1 was moderate and 2 had severe persistent affection.

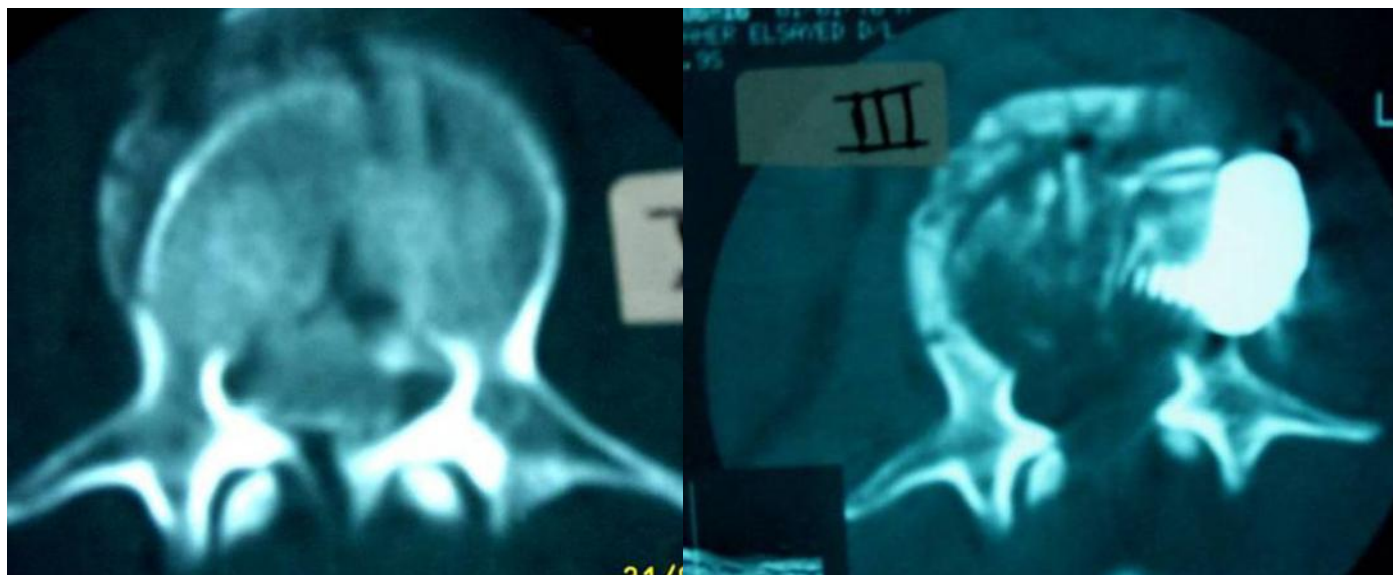
The end results showed statistically insignificant difference with more improvement in anterior group regarding the sexual state and normal marital life.

### Radiological outcome

Kyphotic angle showed significant improvement of both groups at early follow-up; in group I (posterior group), the mean preoperative angle of kyphotic deformity was measured  $22.1 \pm 6.7$  degrees, with significant early postoperative correction to  $5.2 \pm 7.6$  degrees. Regarding group II (anterior group), the mean preoperative angle of kyphotic deformity was measured  $19.4 \pm 7.3$  degrees, with significant early postoperative correction to 6.7 degrees. At the latest radiographic follow-up, the posterior group lost this significance (angulation reverted to an average  $9.9 \pm 3.9$  degrees) (Figure 2), whereas the anterior-only group continued to demonstrate statistically significant improvement in sagittal alignment at follow-up (the mean kyphotic angle was  $6.8 \pm 6.6$  degrees) compared to preoperative measurements  $P = 0.007$ .

The regional kyphosis angle also had been improved significantly in group II and also in group I. In posterior group it is improved from a mean of  $15.8 \pm 9.7$  preoperatively to a mean of  $3.1 \pm 5.4$  at final follow-up. Regarding the anterior fixation group, it is improved from a mean of  $14.6 \pm 8.5$  preoperatively to a mean of  $3.9 \pm 2.2$  at final follow-up.

Regarding canal decompression measured by thin cuts CT scanning, canal encroachment was improved significantly in group II (anterior group) rather than group I (posterior group). In group II; the mean preoperative canal encroachment was 46% of the spinal canal diameter. It was only mean of 8% encroachment of spinal



**Figure 3.** A 34 years old male with significant thoraco-lumbar burst fracture at the level of L1 vertebra with neural compromise A: Retro-pulsed fragment of about 90 % of the neural canal, B: postoperative CT scan shows significant improvement of the neural canal encroachment and the anterior fixation plate.

canal at the last follow-up (Fig. 3 - A, B). On the other hand the mean preoperative canal encroachment was 53% in group I (posterior group); it was changed at the last follow-up to a mean of 31%. This is expected result due to the direct anterior decompression of the spinal cord via the anterior approach compared with the indirect transpedicular decompression of the posterior approach which can not restore the canal to normal dimensions in most cases.

## DISCUSSION

Management of thoracolumbar fractures is one of the most controversial areas in modern spinal surgery. Bracing, recumbency, surgical approaches either anterior or posterior approach (Mahar et al., 2007), and combined procedures all have been advocated (Hitchon et al., 1998). Many studies all over the last two decades have discussed the benefits and hazards of these approaches (Hitchon et al., 1998; Dai et al., 2004; Tian et al., 2008). The late outcome of either approaches needs to be assessed well to decide which will result in a better quality of life in the future.

In our series, neurological recovery in the posterior group was less significant if compared with preoperative state. According to *Frankel Paraplegia Scale* (11), 21 patients (70%) had a neurological deficits, ranged from "Grade D to B" grades, and 6 patients (20%) were on "Grade E", those were still in the best grade of *Frankel Paraplegia Scale* postoperatively and majority of patients with neurological deficits remained on same grades on *Frankle Scale*. The postoperative grading became 33%

on Grade E (without neurological deficits) and 37% on Grade "D".

Neurological recovery in anterior group according to *Frankel Paraplegia Scale* appeared more favorable. As 18 patients (90%) of anterior group had a neurological deficits, ranged from Grade "D" to "B", 15 patients (83%) of those with neurological deficits were improved at least one to two grades above on *Frankel Paraplegia Scale*. The postoperative grading became 53% on Grade E (without neurological deficits) and 27% on Grade D. That was showing highly statistically significant in improving of the clinical and neurological outcome postoperatively in comparing with the preoperative clinical manifestations.

The postoperative improvement regarding the clinical condition was also previously discussed in literatures by (14), they reported that patients who treated through the antero-lateral approach showed better improvement in clinical outcome based on *Frankel Grade* compared with those treated via the posterior approach. Our series differs in the time of final follow up: we evaluate the condition of the patients after a mean of 4.9 years; it gives us a view about the long-term life pattern of those patients after dorsolumbar fixation.

We would attribute this difference of the neurological recovery outcome between the techniques upon the direct and complete decompression of the neural elements (spinal cord, conus and cauda equine) through the antero-lateral approach compared with indirect, and incomplete decompression that result from ligamentotaxis by the posterior techniques that are mainly performed without direct access to the anterior spinal canal, or by disruption of the posterior arch through fenestration or complete laminectomy.



## Functional outcome

In anterior group, functional outcome showed that 76.7% of patients had excellent outcome on the functional Scale, and 20% had good functional results. There was significant difference in comparison with posterior group, as 50% of patients had excellent outcome, and 30% of patients had good functional results. Both groups are considered satisfactory outcome regarding pain relief and return to work. To the extent that surgery maximizes early neurologic recovery and facilitates early mobilization, operative treatment may improve functional outcomes; direct decompression insures the earliest and most complete relief of neural compression. The more aggressive surgical approach does not result in an increased incidence of complications or morbidity, but improvement is never certain. Verlann et al.(2005). have reported the same results as they documented that (83%) of the patients with thoracolumbar vertebral fractures and treated for decompression and fixation through anterolateral approach showed satisfactory functional outcome (excellent to good) on the *Denis Pain and work Scale*, while only (64%) in those treated through posterior approach.

## Radiological outcome

At final radiographic follow-up, there was increase in post-operative kyphosis in the posterior group (loss of the immediate postoperative improvement of sagittal alignment) which is probably secondary to the inability of the posterior group to provide significant anterior column support. The lack of anterior column support allows increased kyphosis to occur and increases the risk of posterior instrumentation failure. These results show the importance of stabilizing the anterior column to maintain sagittal alignment. Progressive kyphosis was noted with the posterior transpedicular stabilization systems (Hak et al., 2009; VanBuren et al., 1992), and increased back pain was found as a late consequence of instrumenting non-fused segments. McLain (2006) and other authors noted failure rates of posterior short-segment pedicle instrumentation ranging from 10% to 50%. After fracture reduction by posterior applied ligamentotaxis, the load bearing anterior column is not reconstituted. The void created by indirect reduction eliminates anterior column load sharing and exposes pedicle screw implants to high cantilever bending loads (Alanay et al., 2001). The relation of clinical and functional outcome with the radiological assessment is clear; the group of patients who subjected to anterior spinal approach was more favorable outcome. It is explained by the finally maintained sagittal alignment which has a role of the pain relief and return to normal life. Also decompression logically could have a role of the motor, sensor and sphincter improvement. Till now, for the concept of

probability of higher complications of anterior spinal surgeries; posterior spinal fixation is still the most widely used. Our results could suggest further trials of learning and applying of the anterior approach.

## CONCLUSION

Restoring the anterior column stability and complete anterior decompression to prevent future increased kyphotic deformity after obtaining initial correction has a long run significant correlation with the overall clinical and functional improvement.

## Disclosure

The Authors have no financial interest in the instrumentation and methodology advanced in this manuscript. The paper complies with the current laws of our country. The study was done after written consent was taken from all the patients and full discussion with them about the benefits and hazard of both approaches of management. The committee of our department had approved the ethical points of the study after full explanation for the patients.

## REFERENCES

- Alanay A, Acaroglu E, Yazici M (2001). Short-segment pedicle instrumentation of thoracolumbar burst fractures. Does transpedicular intracorporeal grafting prevent early failure? *Spine* 26:213–217.
- Alvine GF, Swain JM, Asher MA, Burton DC (2004). Treatment of thoracolumbar burst fractures with variable screw placement or Isola instrumentation and arthrodesis case series and literature review. *J. Spinal Disord Tech.* 17:251–264
- Benson DR, Burkus JK, Montesano PX, Sutherland TB, McLain RF (1992). Unstable thoracolumbar and lumbar burst fractures treated with the AO fixateur interne. *J Spinal Disord.* 5:335–343.
- Cappelleri JC, Rosen RC. The Sexual Health Inventory for Men (SHIM) (2005) a 5-year review of research and clinical experience. *Int J Impot Res*, 17(4):307–319.
- Carl AL, Matsumoto M, Whalen JT (2000) Anterior dural laceration caused by thoracolumbar and lumbar burst fractures. *J Spinal Disorder* 13:339-403.
- Chen ZW, Ding ZQ, Zhai WL, Lian KJ, Kang LQ, Guo LX, Liu H, Lin B (2012). Anterior versus posterior approach in the treatment of chronic thoracolumbar fractures. *Orthopedics*. Feb 17;35
- Dai LY, Jiang SD, Wang XY, Jiang LS (2007). A review of the management of thoracolumbar burst fractures. *Surg Neurol.* 67:221–231.
- Dai LY, Yao WF, Cui YM, Zhou Q (2004). Thoracolumbar fractures in patients with multiple injuries: diagnosis and treatment—a Rev. 147 cases. *J Trauma* 56:348–355.
- Denis F (1983) The three column spine and its significance in the classification of acute thoracolumbar spinal injuries. *Spine* 8:817–831
- Esses SI, Bostfoford DJ, Kosttuik JP (1990). Evaluation of surgical treatment of burst fractures. *Spine* 15:667-672.
- Frankel HL, Hancock DO, Hyslop G, Melzak J, Michaelis LS, Ungar GH (1969). The value of postural reduction in the initial management of closed injuries of the spine with paraplegia and tetraplegia. I. *Paraplegia.*; 7:179–192.
- Fredrickson BE, Edwards WT, Raushning W (1992). Vertebral Burst fractures: An experimental morphological and radiographic

- study. *Spine* 17:1012-1021.
- Gertzbein SD (1992) Scoliosis Research Society. Multicenter spine fracture study. *Spine* 17:528-540.
- Gregory C., Michael J (1999). A new technique for surgical management of unstable thoracolumbar fractures: A modification of the anterior approach and an outcome comparison to traditional methods. *Neurosurg focus* 7(1):article3; 1-18.
- Hak SK., Seung YL, Ankur N (2009) Comparison of Surgical Outcomes in Thoracolumbar Fractures Operated with Posterior Constructs Having Varying Fixation Length with Selective Anterior Fusion. *Yonsei Med J.* August 31; 50(4): 546-554.
- Hitchon PW, Torner JC, Haddad SF, Follett KA (1998) Management options in thoracolumbar burst fractures. *Surg Neurol* 49:619-27.
- Humphries AW, Hawk WA (1958) Anterior fusion of the lumbar spine using an internal fixative device. *Surg Forum* 9: 770-773.
- Kaneda K, Abumi K, Fujita M (1984). Burst fractures with neurologic deficits of thoracolumbar-lumbar spine (1984) Results of anterior decompression and stabilization with anterior instrumentation. *Spine* 9:788-795.
- Korovessis P, Baikousis A, Zacharatos S, Petsinis G, Koureas G, Iliopoulos P (2006) Combined anterior plus posterior stabilization versus posterior short-segment instrumentation and fusion for mid-lumbar (L2-L4) burst fractures. *Spine* 31:859-868
- Mahar A, Kim C, Wedemeyer M, Mitsunaga L, Odell T, Johnson B, et al (2007) Short-segment fixation of lumbar burst fractures using pedicle fixation at the level of the fracture. *Spine (Phila Pa 1976)*. 32:1503-1507.
- McLain RF (2006) The biomechanics of long versus short fixation for thoracolumbar spine fractures. *Spine (Phila Pa 1976)* 31(11) Suppl:S70-S79.
- Prolo DJ, Oklund SA, Butcher M (1986) Toward uniformity in evaluating results of lumbar spine operations: a paradigm applied to PLIF. *Spine*. 11:601-6.
- Roy-Camille R, Roy-Camille M, Demeulenaere C (1970) Osteosynthesis of dorsal, lumbar, and lumbosacral spine with metallic plates screwed into vertebral pedicles and articular apophyses. *Presse Med.* 78:1447-1448.
- Royle ND (1928) The operative removal of an accessory vertebra. *Med J Aust* 1:467.
- Tian H, Song YC, Chen JT, Ma N, Wang C, Xu Q, Ta YE (2008) Systemic review of anterior versus posterior surgical treatments of thoracolumbar fractures. *Zhonghua Wai Ke Za Zhi.* Oct 15;46(20):1562-7.
- VanBuren RL, Wagner FC, Montesano PX (1992) Management of thoracolumbar fractures with accompanying neurological injuries. *Neurosurgery* 30:667-671.
- Verlaan JJ, Dhert WJ, Verbout AJ, Oner FC (2005) Balloon vertebroplasty in combination with pedicle screw instrumentation: a novel technique to treat thoracic and lumbar burst fractures. *Spine* 30:E73-9.
- Willén J, Anderson J, Toomoka K, Singer K (1990) The natural history of burst fractures at the thoracolumbar junction. *J Spinal Disord.* 3:39-46.
- Wood KB, Bohn D, Mehbod A (2005). Anterior versus posterior treatment of stable thoracolumbar burst fractures without neurologic deficit: a prospective, randomized study. *J Spinal Disord Tech.* Feb;18 Suppl:S15-23